

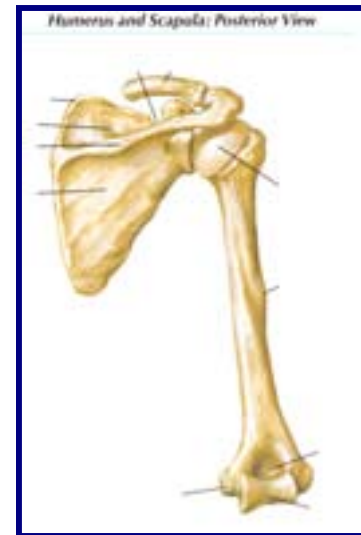
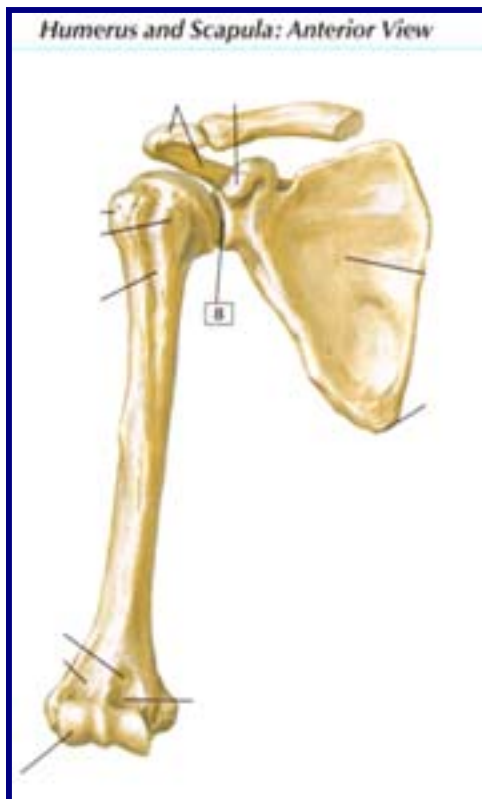
Dissection 2: Shoulder Region and Axilla

Objective 1)

Identify the major processes on the scapula, clavicle and the proximal part of the humerus and their surface projections.

A.) Scapula:

- i. Spine of the Scapula: On post. Side, 1/3 down the body
 1. Divides supra- and infraspinous fossae
 2. Is horizontal and goes medial to lateral
- ii. Acromion: Subcutaneous “point of the shoulder”
 1. C-shaped and bends around to articulate with clavicle



2. For muscle, ligament, and clavicle attachment
- iii. Glenoid cavity: concavity for humeral articulation
- iv. Coracoid process: anteriolateral projection sup. to the glenoid cavity
- v. Suprascapular notch: on superior border medial to the coracoid process
- vi. Supraglenoid tubercle: point at top of glenoid cavity for long head of biceps brachii attachment
- vii. Infraglenoid tubercle: point at bottom of glenoid cavity for long head of triceps brachii attachment
- viii. Spinoglenoid notch: hole through spine connecting supra- and infraspinous fossae; suprascapular n. passes through
- ix. Borders: superior, medial, and lateral

- x. Angles: superior, inferior, lateral (glenoid cavity region)
 - xi. Fossae: subscapular, infraspinous, supraspinous
- B.) Clavicle:
- i. Heads: sternal and acromial
 - ii. Shaft: S-shaped body
 - iii. Deltoid tubercle: bump on post. surface near acromial head
 - iv. Conoid tubercle: bump on inf. side near acromial head
 - v. Trapezoid line: line lat. to conoid tubercle under acromial head
 - vi. *Subclavian groove: groove in shaft
 - vii. *Costal tuberosity: indentation on inf. side near sternal head
- C.) Proximal Humerus:
- i. Head: ball-shaped piece that fits into glenoid cavity
 - ii. Intratubercular groove (sulcus): divides greater and lesser tubercles; muscles attach
 - iii. Greater tubercle: lateral eminence distal to the head for muscle attachment
 - iv. Lesser tubercle: medial eminence distal to the head for muscle attachment
 - v. Anatomical neck: dividing line b/ tubercles and head
 - vi. Surgical neck: distal to tubercles and is the narrowing of humerus before the shaft begins
- D.) Surface projections: clavicle, acromioclavicular joints, acromion angle, crest of scapular spine, and angle and border of scapula

Objective 2)

Identify the joints and ligaments formed between the scapula, clavicle and humerus and the contribution of each joint to the movements of the shoulder.

- E.) Sternoclavicular joint: saddle joint
- i. Joins clavicle and manubrium of sternum
 - ii. Connects upper limb to trunk ant. and acts as strut keeping limb from thorax → only joint b/ upper arm and thorax
 - iii. Allows movements of pectoral girdle and upper limb → ant., post., and inf. movements
 - iv. Ligaments:
 1. Interclavicular ligament: thickened part of capsule that connects clavicles across top of manubrium
 2. Sternoclavicular ligament: (2 → ant. and post.) reinforce capsule
 3. Costoclavicular ligament: anchors inf. surface of clavicle to 1st rib and its cartilage → limits elevation of pectoral girdle
- F.) Acromioclavicular joint: planar joint (p. 481, Netter 394)
- i. 2 to 3 cm from point of shoulder and has partial articular disc
 - ii. Allows rotation of scapula around clavicle and attaches scapula to clavicle and indirectly to thorax
 - iii. Ligaments:
 1. Acromioclavicular ligament: fibrous band from acromion to clavicle to strengthen joint
 2. Coracoclavicular ligament: medial to joint and has two parts
 - a. Conoid ligament: from root of coracoid process to conoid tubercle of clavicle
 - b. Trapezoid ligament: from sup. surface of coracoid process to trapezoid line laterally and posteriorly

- G.) Glenohumeral joint: ball-and-socket joint (p. 481-485, Netter 394)
- i. B/ head of humerus and glenoid cavity
 - ii. Most free joint of body → flexion, extension, adduction, abduction, lateral rotation, medial rotation, and circumduction
 - iii. Ligaments:
 1. Glenohumeral ligaments: 3 → sup., middle, inf. and run from humerus to glenoid cavity to stabilize joint
 2. Coracohumeral ligament: humerus to coracoid process and runs behind other ligaments; strengthens joint
 3. Transverse humeral ligament: bridges gap b/ greater and lesser tubercles to strengthen capsule
 4. Coracoacromial ligament: spans b/ acromion and coracoid process to for part of coracoacromial arch to prevent sup. thrust of humerus

Objective 3)

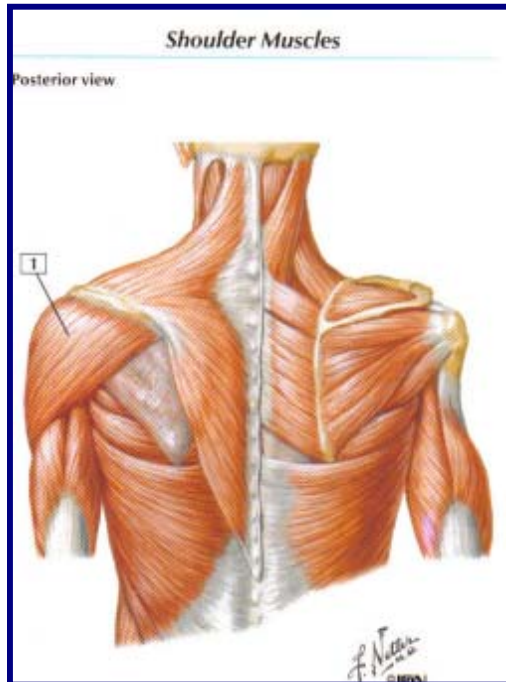
Identify the muscles of the shoulder, axilla and arm; indicate their primary actions and their innervation. Predict the functional consequences of weakness or loss of function of each muscle.

H.) Anterior Thoracoappendicular muscles

- i. Pectoralis major:
 1. Clavicle and sternum to lat. lip of intratubercular groove of humerus and makes up most of ant. axillary fold
 2. Innervated by medial and lateral pectoral nn.
 3. 1^o action → adducts and medially rotates arm
 4. If weak → weak of adduction and medial rotation of arm and floppy ant. axillary fold
- ii. Pectoralis minor:
 1. Ribs 3 to 5 (near costal cartilages) to medial coracoid process deep to pectoralis major
 2. Innervated by medial pectoral n.
 3. 1^o action → stabilizes scapula to by drawing it inf. and ant. to thoracic wall; stretches limb forward
 4. If weak → scapula loose
- iii. Subclavius:
 1. Jxn. Of 1st rib and costal cartilage to inf. surface of middle 1/3 of clavicle
 2. Innervated by nerve to subclavius
 3. 1^o action → anchors and depresses clavicle
 4. If weak → clavicle loose
- iv. Serratus anterior:
 1. External surface of 1st 8 ribs to ant. surface of medial border of scapula; makes up part of medial wall of axilla
 2. Innervated by long thoracic n.
 3. 1^o action → holds scapula to thoracic wall and protracts and rotates scapula
 4. If weak → winged scapula and decreased scapular movement

I.) Posterior Thoracoappendicular and Scapulohumeral muscles:

- i. Trapezius:



1. Innervated by CN XI and C3 and C4
2. 1° action → elevates, retracts, and depresses scapula
3. If weak → weak of scapular motion

ii. Latissimus dorsi:

1. Innervated by thoracodorsal n.
2. 1° action → extends, adducts, and medially rotates arm
3. If weak → weak of extension, adduction, and medial rotation of arm

iii. Levator scapulae:

1. Innervated by dorsal scapular n.
2. 1° action → elevates scapula and rotates it inferiorly
3. If weak → weak of scapular movement

iv. Rhomboids: major and minor

1. Innervated by dorsal scapular n.
2. 1° action → retract scapula and fix it to thoracic wall
3. If weak → loose scapula and weak retraction

v. Deltoid:

1. Lateral 1/3 of clavicle and scapula (acromion and spine) to deltoid tuberosity of humerus → triangular muscle of shoulder
2. Innervated by axillary n.
3. 1° action → flexion and medial rotation (ant. part), abduction (middle part), and extension and lateral rotation (lat. part)
4. If weak → significant arm movement loss and loose rounded shoulder contour

vi. Supraspinatus:

1. Supraspinous fossa to sup. facet of greater tubercle; part of rotator cuff
2. Innervated by suprascapular n.
3. 1° action → hold humerus to glenoid cavity and initiate abduction of arm
4. If weak → loose humerus and trouble starting its abduction

vii. Infraspinatus:

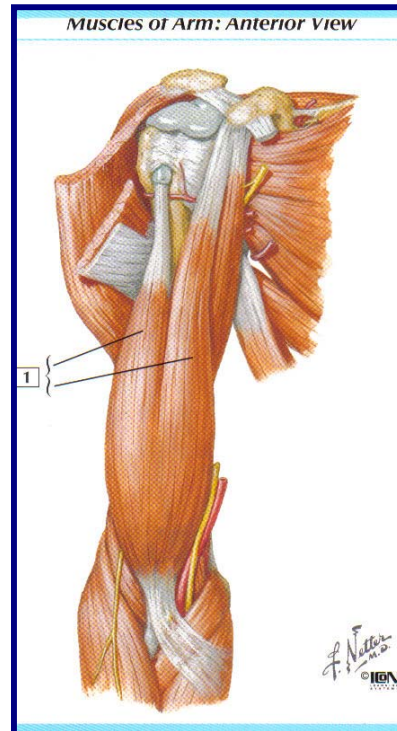
1. Infraspinous fossa to middle facet of greater tubercle; part of rotator cuff
2. Innervated by suprascapular n.
3. 1° action → hold humerus to glenoid cavity and lat. rotation of arm
4. If weak → loose humerus and trouble lat. rotating

- viii. Teres minor:
 1. Superior part of lat. border of scapula to inf. facet of greater tubercle; part of rotator cuff
 2. Innervated by axillary n.
 3. 1° action → hold humerus to glenoid cavity and lat. rotation of arm
 4. If weak → loose humerus and trouble lat. rotating
- ix. Subscapularis:
 1. Subscapular fossa to lesser tubercle; part of rotator cuff
 2. Innervated by upper and lower subscapular nn.
 3. 1° action → hold humerus to glenoid cavity and medial rotation of arm
 4. If weak → loose humerus and trouble medially rotating
- x. Teres major:
 1. Dorsal surface of scapula to medial lip of intratubercular groove
 2. Innervated by lower subscapular n.
 3. 1° action → adducts and medially rotates arm
 4. If weak → less adduction and medial rotation of arm

J.) Arm muscles:

i. Biceps brachii:

1. Short head from tip of coracoid process, long head from supraglenoid tubercle, and both to tuberosity of radius and cuboidal fossa
2. Innervated by musculocutaneous n.
3. 1° action → supinates forearm and flexes it when supine
4. If weak → weak forearm supination and flexion



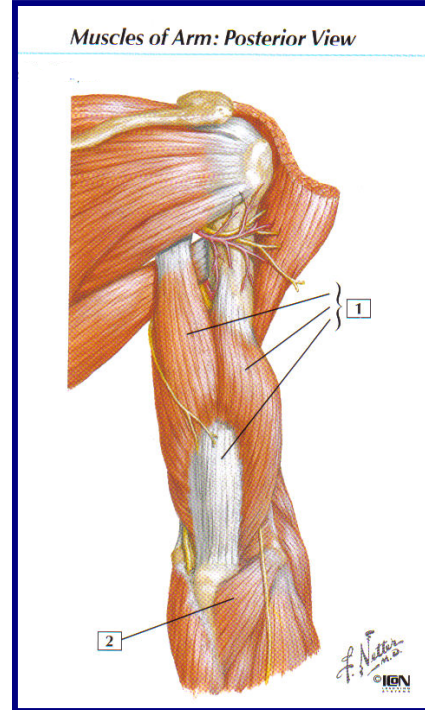
ii. Brachialis:

1. From distal half of ant. surface of humerus to coronoid process and tuberosity of ulna
2. Innervated by musculocutaneous n.
3. 1° action → flexion of forearm
4. If weak → weak, unsteady flexion of forearm

iii. Coracobrachialis:

1. Tip of coracoid process to middle 1/3 medial surface of humerus
2. Innervated by musculocutaneous n.
3. 1° action → helps flex and adduct arm
4. If weak → weak flexion and adduction of arm

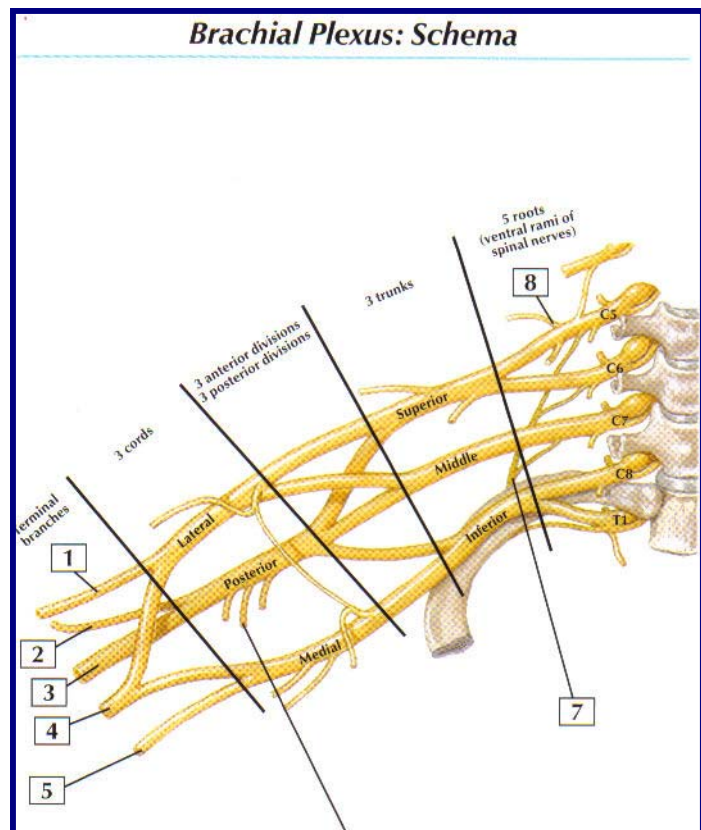
- iv. Triceps brachii:
1. Long head from infraglenoid tubercle, lateral head from post. humerus sup. to radial groove, medial head from post. humerus inf. to radial groove, and all 3 to proximal end of olecranon
 2. Innervated by radial n.
 3. 1^o action → extends forearm
 4. If weak → little extension of forearm
- v. *Anconeus:
1. Lateral epicondyle of humerus to lat. surface of olecranon and sup. post. ulna
 2. Innervated by radial n.
 3. 1^o action → helps extend forearm and stabilizes elbow
 4. If weak → unstable elbow and weaker extension



Objective 4)

Identify the component parts of the brachial plexus, the segmental source of origin, and the termination of each. Indicate how the different components contribute to the cutaneous and motor innervation of the shoulder region. Given a lesion to any part of the brachial plexus, predict the sensory and motor deficits, which would be expected.

- K.) Roots: ant. ventral rami of C5, C6, C7, C8, and T1
- i. Located @ post. triangle of neck and pierce scalene hiatus
- L.) Trunks: roots come together as they emerge from scalene hiatus
- i. Superior trunk: C5 and C6 roots combine
 - ii. Middle trunk: C7 root remain alone
 - iii. Inferior trunk: C8 and T1 roots combine
 - iv. Run from scalene hiatus to 1st rib; pass from neck to axilla through cervicoaxillary canal posteriorly



- M.) Divisions: each trunk splits into anterior and posterior divisions
- i. Ant. divisions innervate ant. aspects of limb
 - ii. Post. divisions innervate post. aspects of limb
- N.) Cords: w/in axilla when divisions combine into 3 cords
- i. Lateral cord: ant. divisions of superior and middle trunks
 - ii. Medial cord: ant. divisions of inferior trunks
 - iii. Posterior cord: post. divisions of all 3 trunks
 - iv. Cords named for anatomical orientation around axilla a.
- O.) Branches:
- i. Lateral cord:
 1. Lateral pectoral nerve: side branch of lateral cord and pierces clavipectoral fascia and innervates pectoralis major
 2. Musculocutaneous nerve: terminal branch of lateral cord that pierces coracobrachialis and runs b/ biceps brachii and brachialis; supplies ant. compartment of arm and ends as lateral cutaneous nerve of forearm
 - ii. Medial cord:
 1. Medial pectoral nerve: side br. of medial cord; pierces pectoralis minor, supplies it and pectoralis major; lateral to lateral pectoral n.
 2. Medial brachial cutaneous nerve (medial cutaneous nerve of arm): side br. of medial cord; supplies skin of medial side of arm and sup. forearm
 3. Medial antebrachial cutaneous nerve (medial cutaneous nerve of forearm): side br. of medial cord; runs b/ axillary a. and v. to supply medial skin of forearm
 4. Ulnar nerve: terminal br. of medial cord; goes through arm, supplies 1 and 1/2 muscles of forearm, medial skin, and intrinsic mm. of hand
 - iii. Posterior cord:
 1. Upper subscapular nerve: side br. of posterior cord; passes posteriorly to pierce subscapularis
 2. Thoracodorsal nerve: side br. of posterior cord; runs inferiorly to latissimus dorsi
 3. Lower subscapular nerve: side br. of posterior cord; passes inferiolaterally deep to subscapular a. and v. to subscapularis and teres major
 4. Axillary nerve: terminal br. of posterior cord; supplies teres minor as it leaves quadrangular space, supplies deltoid from deep post. aspect, and continues superiorly as lateral cutaneous nerve of arm
 5. Radial nerve: terminal br. of posterior cord; largest br. of brachial plexus; supplies all exterior muscles of post. compartment of upper arm and forearm and skin of post. arm
 - iv. Median nerve: formed by lateral and medial roots of lateral and medial cords, respectively; supplies ant. flexor compartment of forearm, skin of part of hand, and 5 hand mm.
 - v. Dorsal scapular nerve: from ant. ramus of C5; pierces scalenus medius and descends to levator scapulae and rhomboids to supply them
 - vi. Long thoracic nerve: formed from ant. rami of C5-C7; descends post. to C8 and T1 ant. roots to external surface of serratus anterior to supply them
 - vii. Suprascapular nerve: off of superior trunk; passes laterally across post. triangle of neck through suprascapular notch under superior transverse

- scapular ligament to innervate supraspinatus, infraspinatus, and glenohumeral joint
- viii. Nerve to subclavius: off of superior trunk; descends posteriorly to clavicle and ant. to brachial plexus and subclavian a. to innervate subclavius and sternoclavicular joint

Objective 5)

Trace the flow of blood from the aorta to the dorsal surface of the scapula and shoulder joint. Identify the different vessels contributing to this vascular network and list all known collateral connections.

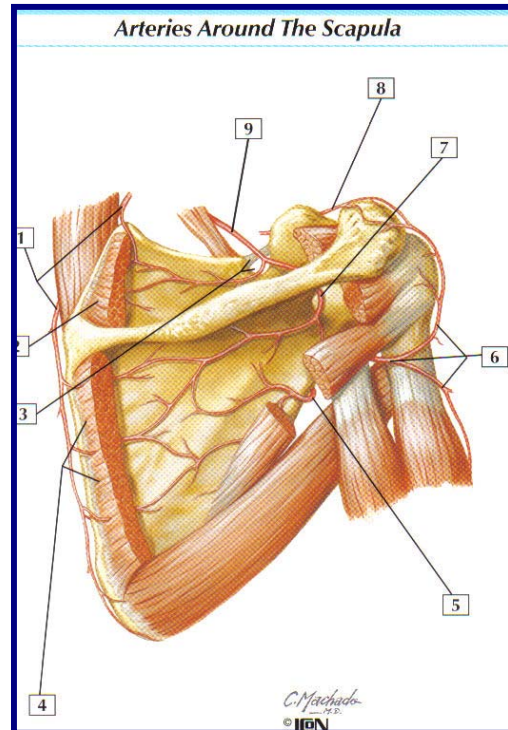
P.) Blood flow: ascending aorta → aortic arch → brachiocephalic trunk (right side only) → subclavian a. → axillary a. →

Q.) 1st part of axillary a. (medial to pectoralis minor):

- i. *Superior thoracic artery: runs anteriomedially along superior border of pectoralis minor and passes b/ it and pectoralis major to thoracic wall to supply 1st and 2nd intercostal spaces

R.) 2nd part of axillary a. (deep to pectoralis minor):

- i. Thoracoacromial trunk: runs around superomedial border of pectoralis minor, pierces clavipectoral fascia, and divides into deltoid, pectoral, clavicular, and acromial branches
- ii. Lateral thoracic artery: descends along axillary border of pectoralis minor and follows it to thoracic wall
- iii. 3rd part of axillary a. (lateral to pectoralis minor):
- iv. Subscapular artery: descends along lateral border of subscapularis and axillary border of scapula to its inf. angle, where it passes to thoracic wall
 1. Thoracodorsal artery: continues course of subscapular a. and accompanies thoracodorsal n.
 2. Circumflex scapular artery: br. from subscapular a. and curves around axillary border of scapula and enters infraspinous fossa
- v. Anterior circumflex humeral artery: circles ant. to surgical neck of humerus to anastomose with posterior circumflex humeral a.
- vi. Posterior circumflex humeral artery: circles post. to surgical neck of humerus to anastomose with anterior circumflex humeral a.; is larger and passes through quadrangular space with axillary n.



S.) Subclavian a. → thyrocervical trunk →

- i. Suprascapular artery: passes inferiolaterally over ant. scalene m. and phrenic n., crosses subclavian a. and brachial plexus, and runs laterally posterior and parallel to clavicle; it then passes to post. aspect of scapula and supplies supraspinatus and infraspinatus
 - ii. Transverse cervical artery: passes laterally to scapula and supplies vessels to anastomoses of dorsal scapular at superior angle
 - 1. ?Dorsal scapular artery?: branch from transverse cervical a. that follows medial border of scapula and supplies vessels for dorsal scapular anastomoses
- T.) *Axillary a. → brachial a. (as it passes teres major) →
- i. *Profundus brachii artery (deep artery of arm): branches off brachial a. near its origin and accompanies radial n. in radial groove to supply deep arm and anastomose at elbow
 - ii. *Superior ulnar collateral artery: at middle of arm branches off and flows ulnar n. to elbow
 - iii. *Inferior ulnar collateral artery: from brachial artery to form ant. and post. parts and goes to elbow

Objective 6)

Trace the flow of lymph into and out of the axillary lymph nodes. Identify the anatomical location of different groups of lymph nodes (whether or not they are actually present in your cadaver), their relationship to other axillary structures, and afferent sources and efferent targets of each group. Follow the course of lymphatic drainage of the breast.

U.) Apical group of axillary lymph nodes:

- i. Located @ apex of axilla along the medial side of axillary v. and 1st part of axillary a.; @ ant./sup. pectoralis minor border
- ii. Afferent sources: all other axillary lymph node groups and lymphatics accompanying proximal cephalic v.
- iii. Efferent targets: subclavian lymphatic trunk

V.) Pectoral (anterior) group of axillary lymph nodes:

- i. Located along medial wall of axilla, around lateral thoracic v. and inferiorlateral border of pectoralis minor
- ii. Afferent sources: from ant. thoracic wall and breast
- iii. Efferent targets: central and apical axillary lymph nodes

W.) Subscapular (posterior) group of axillary lymph nodes:

- i. Located along posterior axillary fold and subscapular blood vessels
- ii. Afferent sources: ipsilateral upper quadrant of back
- iii. Efferent targets: central and apical axillary lymph nodes

X.) Humeral (lateral) group of axillary lymph nodes:

- i. Located along lateral wall of axilla around distal part of axillary v.
- ii. Afferent sources: almost all the lymph from upper arm, except lymph carried by vessels traveling w/ cephalic v.
- iii. Efferent targets: central and apical axillary lymph nodes

Y.) Central group of axillary lymph nodes:

- i. Located deep to pectoralis minor in association w/ 2nd part of axillary a.
- ii. Afferent sources: pectoral, humeral, and subscapular groups of axillary lymph nodes
- iii. Efferent targets: apical group of axillary lymph nodes

Z.) Lymph flow: upper limb to Humeral nodes, upper quadrant of back to Subscapular nodes, anterior thoracic wall and breast to Pectoral nodes → Central nodes and lymphatic traveling w/ cephalic v. → Apical nodes → subclavian lymphatic trunk → right lymphatic duct or right venous angle or thoracic duct on left

AA.) Lymphatic drainage of breast:

- i. Lymph passes from nipple, areola, and lobules of the gland to subareolar plexus.
- ii. 75% of lymph, especially from lateral breast, drains into axillary lymph nodes (mostly pectoral nodes).
- iii. Other lymph, especially medial breast, drains to parasternal lymph nodes or other breast.
- iv. Lymph from lower breast to inferior phrenic (abdominal) lymph nodes.